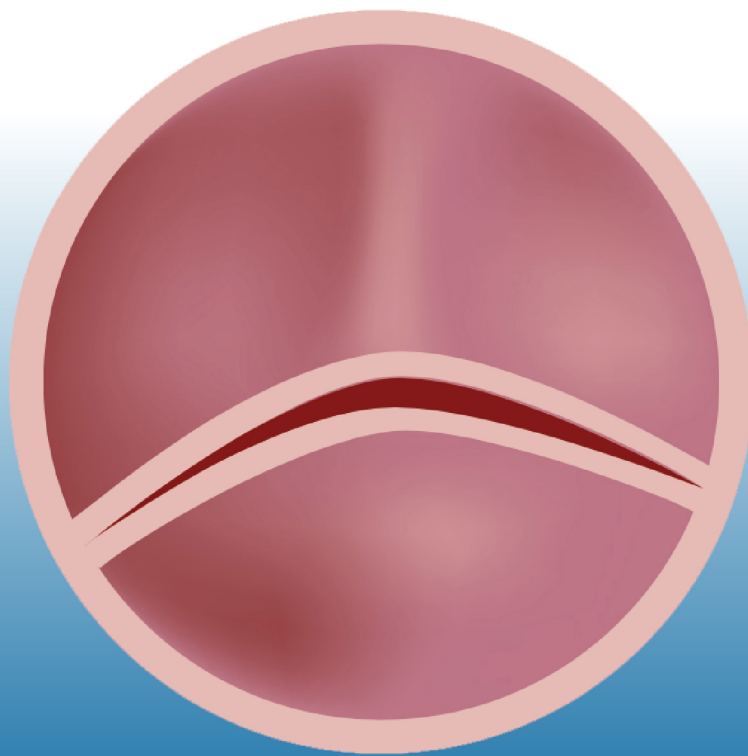


Advances in Bicuspid Aortic Valve Therapy



Authors

Dr. S. Chris Malaisrie
Cardiac Surgeon
Northwestern Medicine
(888) 771-3407

Dr. Jyothy Puthumana
Cardiologist
Northwestern Medicine
(888) 771-3407


Adam Pick
Patient & Website Founder
HeartValveSurgery.com
(888) 725-4311

Table of Contents

| | |
|--|----|
| Authors | 4 |
| Introduction | 5 |
| Overview | 8 |
| About Bicuspid Aortic Valves | 10 |
| Different Types of Bicuspid Aortic Valves | 12 |
| Prevalence of Bicuspid Aortic Valves | 14 |
| Bicuspid Aortic Valve Disease Types | 15 |
| Aortic Aneurysm & Bicuspid Aortic Valves | 16 |
| Life Expectancy Resulting from Bicuspid Aortic Valve | 18 |
| Family Screening for Bicuspid Aortic Valves | 20 |
| Treatment Options | 22 |
| Valve Replacement Options | 23 |
| Replacing the Aorta Using the Bentall Procedure | 25 |
| Valve-Sparing Aortic Root Replacement | 27 |
| The Ross Procedure | 28 |
| Minimally-Invasive Approaches | 29 |
| Transcatheter Aortic Valve Replacement (TAVR) | 31 |
| Northwestern’s Bicuspid Aortic Valve Program | 33 |
| Researching Bicuspid Aortic Valves | 34 |
| Valve Fusion & Flow Patterns | 35 |
| 4D-MRI Research | 36 |

| | |
|---|----|
| 4D-MRI & Tissue Correlations | 38 |
| Questions & Answers | 40 |
| Bicuspid Aortic Valve Progression | 40 |
| Tissue Valve Re-Operations | 42 |
| Aortic Aneurysm Surgery Timing | 43 |
| Risk Factors & Concerns | 44 |
| Dental Infections | 46 |
| SAVR v. TAVR Restrictions | 48 |
| Symptoms & Concerns | 49 |
| Homograft Replacements | 51 |
| Mechanical Valves, Blood Thinners & PROACT Xa Trial | 52 |
| Educational Resources | 54 |

Authors



Dr. S. Chris Malaisrie

Cardiac Surgeon
Northwestern Medicine
Chicago, Illinois
(888) 771-3407

[Learn more](#)



Dr. Jyothy Puthumana

Cardiologist
Northwestern Medicine
Chicago, Illinois
(888) 771-3407

[Learn more](#)



Adam Pick

Patient & Website Founder
HeartValveSurgery.com
Los Angeles, California
(888) 725-4311

[Learn more](#)

Introduction



The slide features a purple header with the HeartValveSurgery.com logo. Below this is a white section with the text "Patient Webinar" and "Advances in Bicuspid Aortic Valve Therapy". A purple section below that is titled "Webinar Speakers" and contains three columns, each with a headshot and name: Dr. S. Chris Malaisrie (Cardiac Surgeon, Northwestern Medicine), Dr. Jyothy Puthumana (Cardiologist, Northwestern Medicine), and Adam Pick (Patient & Website Founder, HeartValveSurgery.com).

Adam Pick: Hi, everybody. My name is Adam Pick, and I'd like to welcome you to the webinar titled, "Advances in Bicuspid Aortic Valve Therapy". If I have yet to meet you, I'm a patient and the founder of HeartValveSurgery.com. Our mission is simple. We want to educate and empower heart valve patients from diagnosis through recovery. This webinar, which had over 400 registrations - from patients in countries all over the world - is designed to support that mission.

During the webinar, all participants are going to be in what we call "listen-only" mode. That being said, you can submit questions during the webinar. Simply post your questions in the control panel on your screen. We will do our best to address your questions during the "Questions &Answers" section at the end of the webinar.


I am thrilled to introduce you to the featured speakers for this session. Dr. Chris Malaisrie is a cardiac surgeon, professor of surgery and co-director of

the Bicuspid Aortic Valve Program at the Bluhm Cardiovascular Institute at Northwestern Medicine.

Dr. Jyothy Puthumana is a cardiologist, associate professor of medicine, and he is also a co-director of the Bicuspid Aortic Valve Program at Northwestern Medicine.

When it comes to bicuspid aortic valves, we have two leading and very talented doctors with us today.

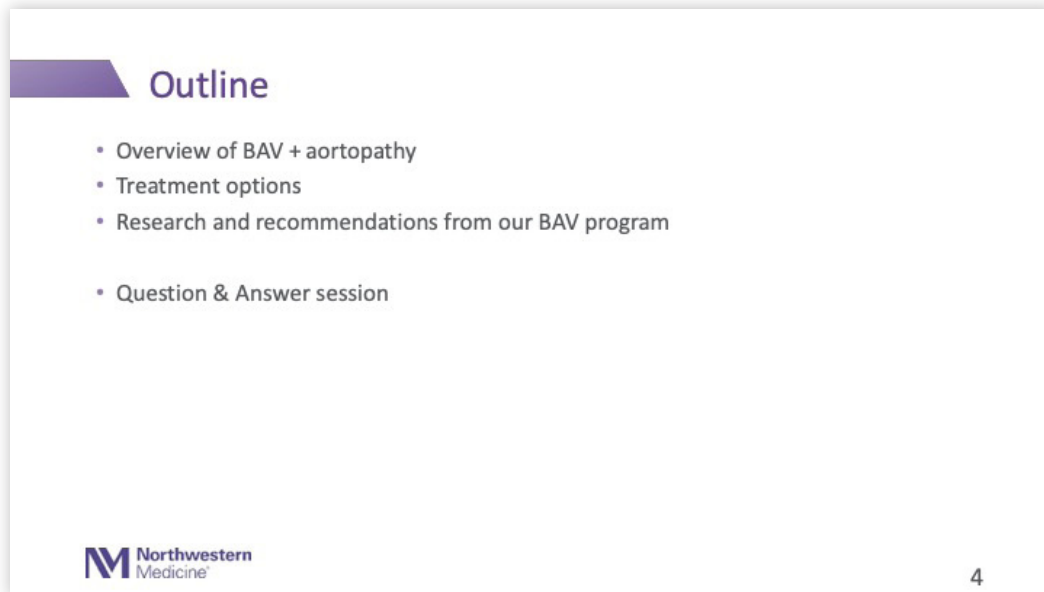
I could go on-and-on about the careers of Dr. Malaisrie and Dr. Puthumana and their special achievements in cardiac care. Instead, I will simply tell you that this team is celebrated by the bicuspid aortic valve patients in our community.



Since launching HeartValveSurgery.com, Northwestern has successfully treated well over a hundred patients from our community. In this slide, you see some of the wonderful faces of patients including Tom Tansor, Jean Frank, Jim Whitney, Janice Kielbasa and the list goes on-and-on-and-on.

I am humbled that Dr. Malaisrie and Dr. Puthumana are taking time away from their very busy practices at Northwestern to share their experiences and clinical research during this educational webinar. I would like to introduce you all to Dr. Chris Malaisrie.


Overview



Outline

- Overview of BAV + aortopathy
- Treatment options
- Research and recommendations from our BAV program

- Question & Answer session

 Northwestern
Medicine®

4

Dr. Chris Malaisrie: Thank you very much, Adam! Welcome to all the participants today. We have a really exciting webinar, which is patient-focused. Over the next hour, we're going to share with you what we've learned through our clinical and research mission in our Bicuspid Aortic Valve Program at Northwestern Medicine, which is made possible by a philanthropic grant from the Melman family.

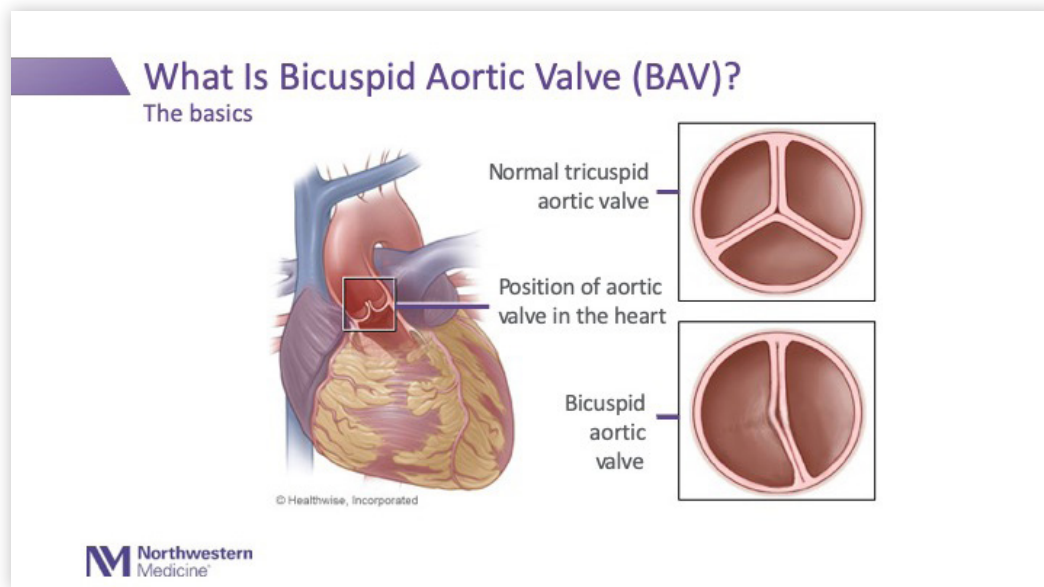
My name is Chris Malaisrie. I'm a cardiac surgeon at Northwestern in downtown Chicago. I am joined here by my colleague and good friend Jyothy Puthumana who is a cardiologist at Bluhm Cardiovascular Institute.

Over the next hour, our outline of the talk will be an overview of bicuspid aortic valve disease and the accompanying disease of the aorta. Patients with bicuspid aortic valve will oftentimes have an associated aortic aneurysm.

The second topic we'll be talking about will be treatment options for patients who have bicuspid aortic valve who then go on to develop disease because of the bicuspid aortic valve or because of aortic aneurysm.

Our last subject will focus on exciting research that we've been doing in bicuspid aortic valve and also give some recommendations on what to look for in treatment options in the future. We'll finish the session with Questions & Answers. I think that will round out the last bit of the hour that we have with you today.

About Bicuspid Aortic Valves

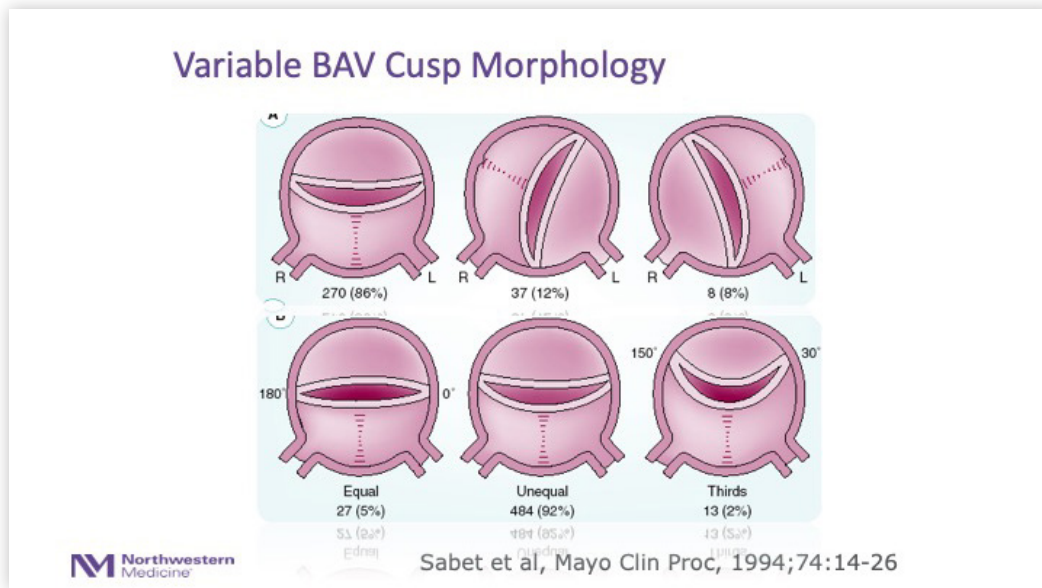


Dr. Jyothy Puthumana: Thanks Adam for having this webinar and a special thanks to all the patients who are joining us today. We hope to cover things that would be of interest and leave enough time so that we can address your questions that come up. As Adam and Chris mentioned, I'm a cardiologist with an interest and expertise with bicuspid aortic valve disease and the medical management of patients. I work very closely with Chris on the patients that we take care of together.

Most of you who signed on today are very familiar with this, but just to set the ground for our discussion, you're familiar that 98% of the patients are born with three leaflets in aortic position, the main valve through which the heart pumps blood to the rest of the body.

In about 2% of people - slightly more in men than in women - the leaflets do not separate in the time of birth leading to bicuspid aortic valve where two of the leaflets do not separate and the patient is left with two leaflets instead of three leaflets in the aortic position.

Different Types of Bicuspid Aortic Valves



Dr. Jyothy Puthumana: There is a different type of morphology for bicuspid aortic valves. It depends on which leaflet did not separate at birth. This picture highlights what is most commonly seen and what is reported in the literature. The most common morphology in a bicuspid valve is where the right and the left cusps are fused together. If you look at this particular image, the top left image, it shows that 86% of patients that we see, and that have been reported in the literature, have the most common right-left fusion pattern.

What is shown there is the two coronary arteries, the arteries that take blood from the heart, originate from the location of the right and the left cusp, and that, again, comes into play when we are talking about potential interventions and surgery with bicuspid patients.

The other point I want to make from this slide is that the leaflets that you see are not equal. When patients have three leaflets, all three leaflets tend to be equal. As expected, when there is fusion of the leaflets, the leaflet that is fused tends to be larger, and that comes into play when we're talking to patients who may be candidates for certain therapies.

Prevalence of Bicuspid Aortic Valves



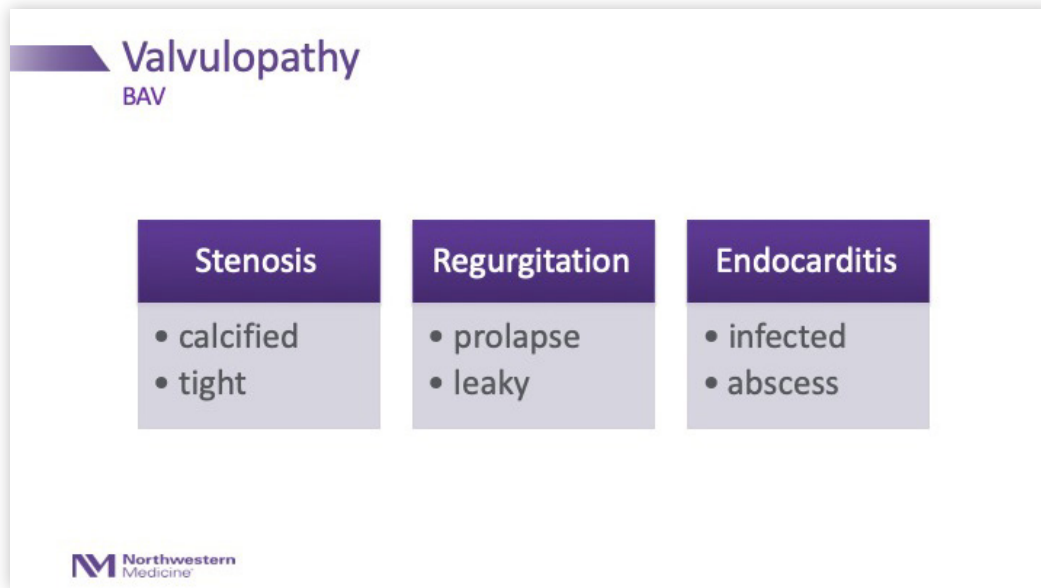
2%

Up to 2% of people have bicuspid aortic valve

Dr. Jyothy Puthumana: Bicuspid aortic valve is reported to be the most common congenital abnormality. Up to 2% of people have a bicuspid valve.

Like one of my colleagues from Lurie Children's Hospital likes to say... If you're in a room with a hundred people, it's likely that there's at least going to be two people in that room that have a bicuspid valve. It is a very common condition - more common in men than in women. It's about one and a half times more common in men.

Bicuspid Aortic Valve Disease Types

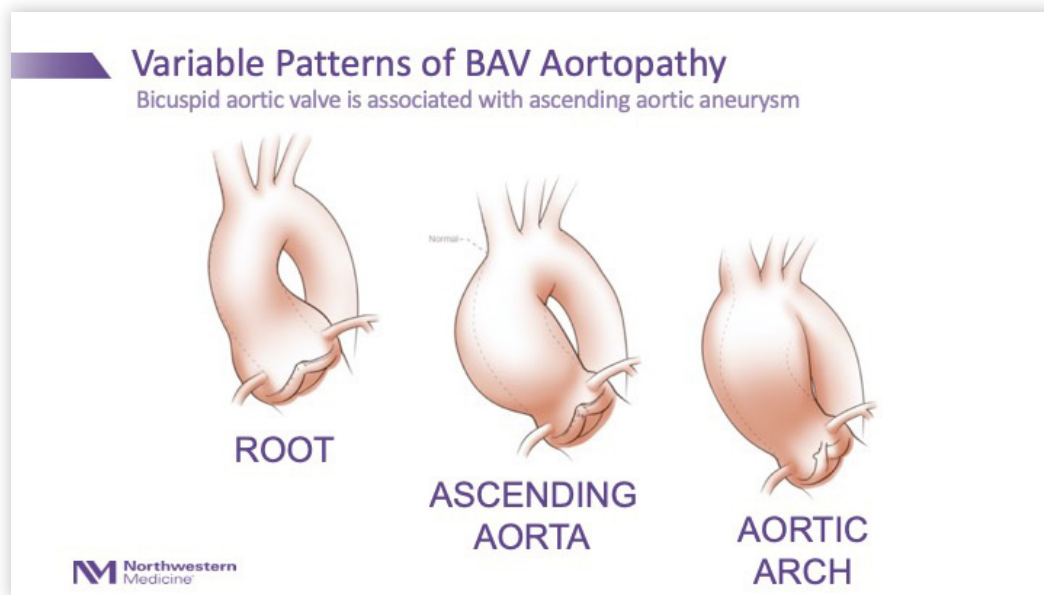


Dr. Jyothy Puthumana: What are the lifetime risks of having a bicuspid valve?

Most of you are familiar with the three conditions that your cardiologist probably talk to you about when they see you in clinic. Or, if you are a new patient, these are the conditions that you should be educated about regarding your valve.

The three things that happen to a bicuspid aortic valve is a narrowing of the valve, or **stenosis**. The second problem that can happen is **regurgitation**, or leaking of the valve, where the valve does not close very well. Then, because of the valve being an abnormal valve and the blood flow across it being abnormal, patients are at risk for **infection**. This particular slide covers the gamut of the valve-related problems that happen in patients with bicuspid valve disease.

Aortic Aneurysm & Bicuspid Aortic Valves



Dr. Jyothy Puthumana: Here you see the manifestations of aneurysms that occur in about 40% of bicuspid aortic valve patients. Luckily, we have a lot of data on bicuspid valve patients over 25 to 30 years of follow-up from a couple of the large studies across the world.

The research has shown that about 40% of patients - when followed up long enough - are likely to develop aortopathy, the presence of an aneurysm. As you see in this slide, there are three different locations where aneurysms tend to form with bicuspid aortic valve disease.

When your doctors say that there is an enlargement of the root, it is the part of the aorta just above the valve that is enlarged. Usually it's the sinuses, the pockets into which the valve sits, that are enlarged.

The more common enlargement of the aorta is the second image on this slide where the aorta further up above the valve is enlarged. This is called ascending aortic dilation. It is an important image to keep in mind because some of these enlargements may not be picked up on an echocardiogram. As you see, this is further up on the aorta, and you can again see in this image that aortic enlargement can be eccentric. That mean the outer curvature is relatively larger than the inner curvatures.

The third image on this slide is where the enlargement of the aorta is not limited to just the proximal but extends into the arch. As you see, the arch is the "candy cane" of the aorta where the aorta comes, takes a turn, and dips down. That's an important part of the aorta where all the blood vessels that take blood to your brain are present. That part of the aorta has significant implications in terms of surgical management because some surgeries include blood flow to the brain.

The good news that has come from this research and other databases is that as long as we know about the diagnosis and as long as we follow patients carefully, patients with a bicuspid aortic valve disease tend to have the same life expectancy as someone who does not have a bicuspid aortic valve disease.


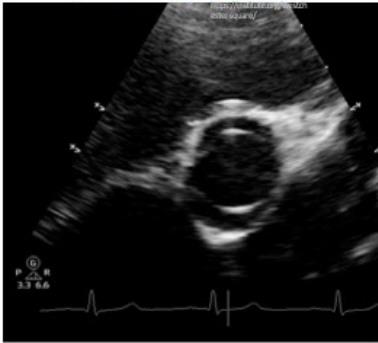
I think the key take-home from this slide that I hope all of you will get is that it is a common diagnosis. It is a diagnosis that has important implications for life. But, as long as a patient is aware of it and follows it up closely, the outcomes are as good as someone without a bicuspid valve.


Family Screening for Bicuspid Aortic Valves

Family Screening for BAV

- 10-15% of patients with BAV report another family member with BAV

- Screening is non-invasive ultrasound of the heart (transthoracic echocardiography)



Dr. Jyothy Puthumana: What is the role of family screening? We know that I mentioned in the initial slide that bicuspid aortic valve impacts 2% of the population.

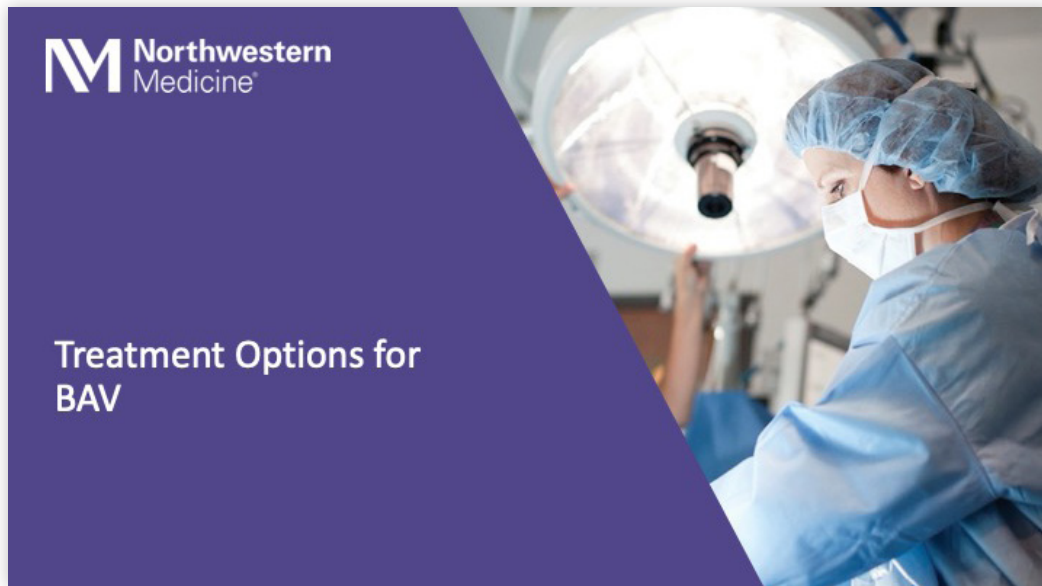We know from a couple of studies that have looked at families of patients with a bicuspid valve that a first-degree relative may be five to seven times more. So, one of the things that we routinely tell our patients the first time is that we get a detailed history about their siblings, about their children, about their parents, just to make sure that we emphasize that fact that this is genetic and runs in families. **If a patient has a presence of a bicuspid valve, we want to make sure that their children are screened.** That screening is traditionally performed using an echocardiogram.

As you see here on this moving image on the right... That is an image of a

bicuspid valve, where – and this is a nicely functioning valve where the two, the fused and the non-fused leaflets, are about the same size. So, the screening is a simple, 45-minute to a one-hour ultrasound of the heart, just like an ultrasound in a mother who's pregnant.

Either someone has a bicuspid valve or they do not. This is recommended by the American College of Cardiology, by the American Heart Association, and the American Academy of Pediatrics. This is an important take-home message that among the patients who have a bicuspid aortic valve, you should encourage your family members, specifically your children and your siblings, to have an echocardiogram, which is the only way to make a diagnosis.



Treatment Options



Dr. Chris Malaisrie: It's really important for patients to know that treatment options very much depend on why the bicuspid aortic valve is diseased. So, if it's tight or calcified, or if it's stretched out and leaky, or if by some unfortunate event the valve becomes infected. These conditions all determine what sort of treatment options we choose for our patients because there are several to think about.

Valve Replacement Options

Valve Replacement Options

| | |
|---|---|
| <p>Tissue Valve</p> <ul style="list-style-type: none">• Less durable• May require reoperation in the future  | <p>Mechanical Valve</p> <ul style="list-style-type: none">• Requires life-long blood thinners• Increased risk of internal bleeding  |
|---|---|

M Northwestern
Medicine®

Dr. Chris Malaisrie: The first treatment option, which is probably the most important one, is if we're to replace the diseased aortic valve, what would the patient want for an artificial valve?

Here are two artificial valves in broad categories.

The one on the left is a tissue valve. You see that the leaflets of that tissue valve are made of either cow or pig. So, they come in two varieties. They are both tissue valves.

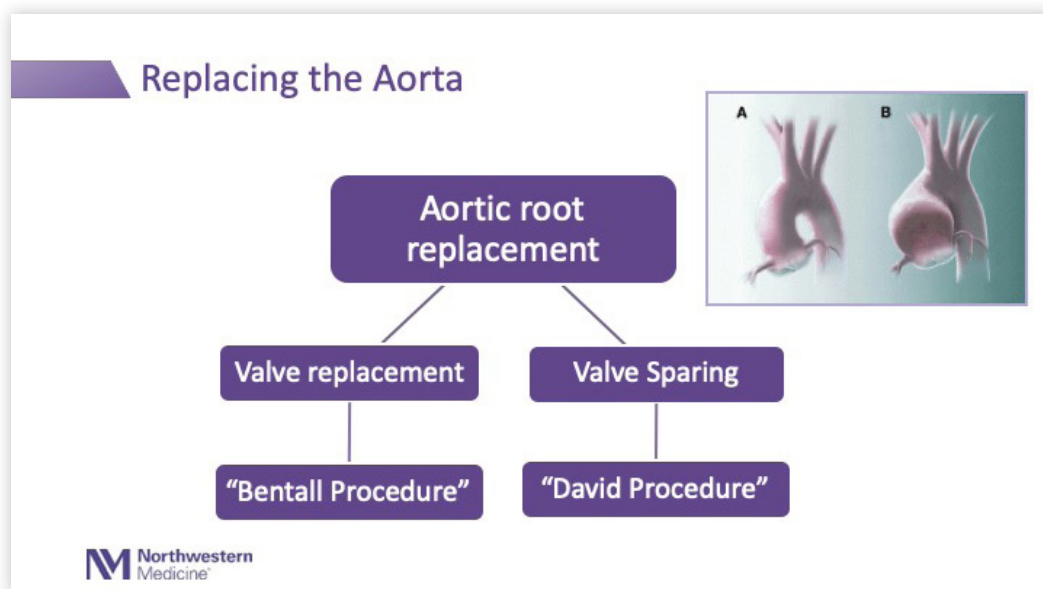
The valve on the right is a mechanical valve. It is actually not metal. It's mechanical in that it's made out of a pure carbon. These do not set off alarms in the airport but these are extremely durable. That is the main benefit of mechanical valves is its durability because that high-grade carbon will never break. It never fractures. It will always open and close as the way it should.

But the downside of the mechanical valve is that patients have to be maintained on a blood thinner. The blood thinner is Warfarin or Coumadin and that requires a once-a-day pill that has to be monitored with blood levels.

On the one hand, the mechanical valve is durable but you have to be on long-term blood thinners. The tissue valve, on the other hand, does not need to be maintained on long-term blood thinners but the durability isn't quite as good as a mechanical valve.

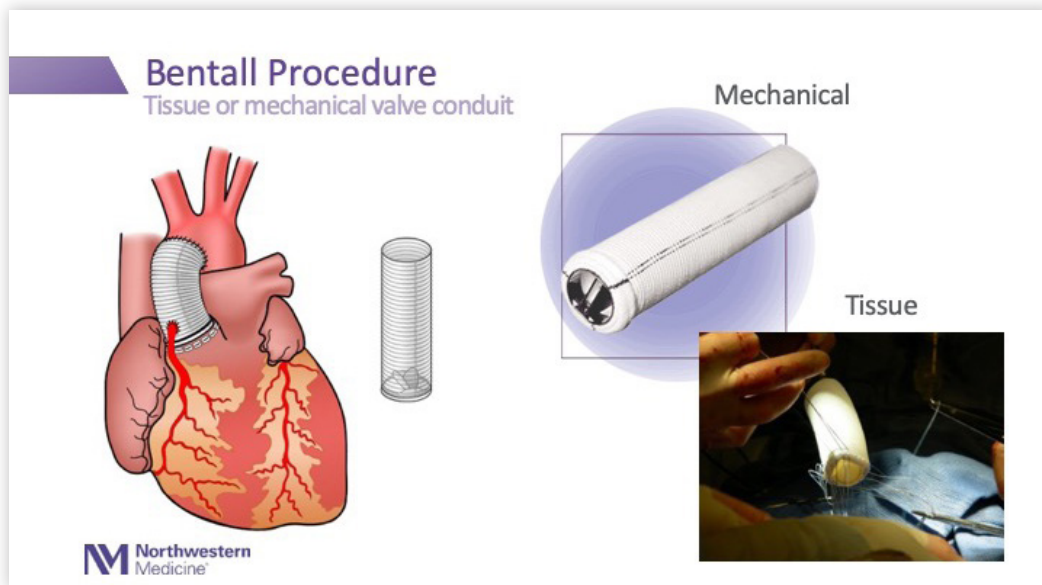
So patients, especially young patients, will be looking at a re-operation in the future. This is such an important question that I recommend patients talk very closely with their cardiologist and cardiac surgeon to determine which is the right valve for you.

Replacing the Aorta Using the Bentall Procedure



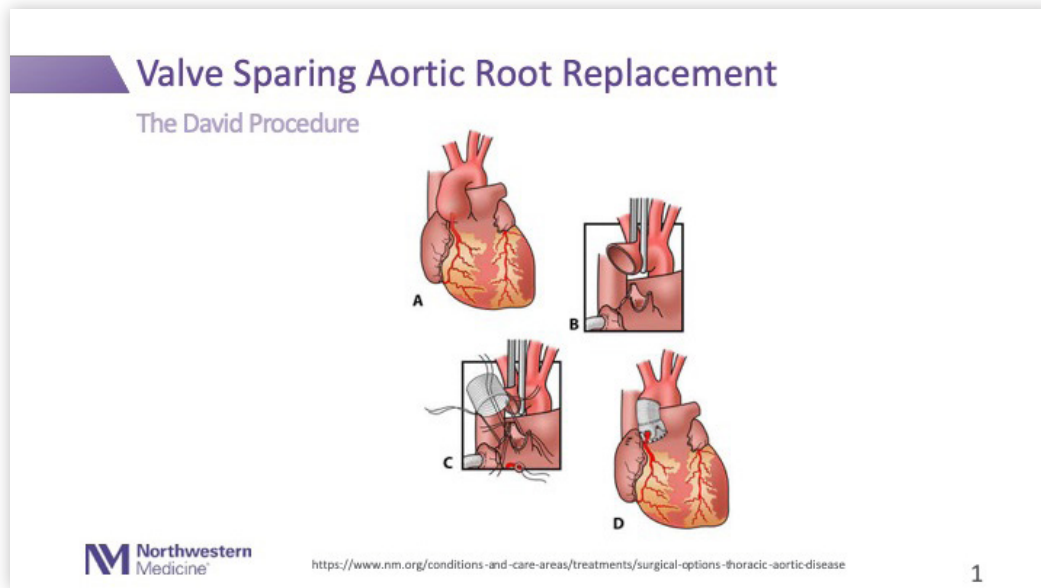
Dr. Chris Malaisrie: The second operation that we do for patients with bicuspid aortic valve are for patients who have an aneurysm with their bicuspid aortic valve. In this treatment, we have to replace the aorta and the valve at the same time, otherwise known as the aortic root replacement. That is what probably most surgeons would offer patients with a bicuspid aortic valve with an aneurysm. It's called a Bentall procedure, named after a surgeon named Hugh Bentall. That's a complete root replacement of the valve and the aorta.

What a lot of people do not know is the bicuspid aortic valve oftentimes can be spared and even repaired. Patients with leaky, stretched out valves are good candidates for a valve repair, and that is called a "valve sparing root replacement" or the David procedure.



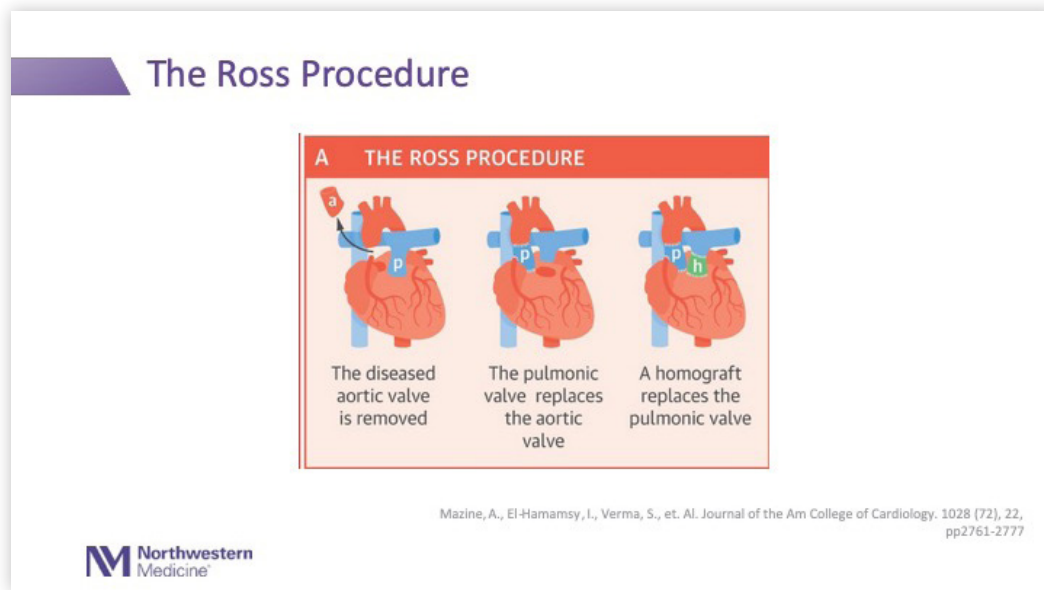
Dr. Chris Malaisrie: This is a schematic of the total root replacement, otherwise known as the Bentall procedure. In this procedure, both the aortic valve is removed, the aneurysm is also removed, and it is replaced with its conduit. The conduit is constructed of either a tissue or a mechanical valve attached to a Dacron graft. Dacron is a textile. It's woven into a machine into a perfect tube, and that is the replacement part for the valve and the aorta.

Valve Sparing Aortic Root Replacement



Dr. Chris Malaisrie: The valve sparing aortic root replacement is a procedure where the valve is deconstructed from the aortic root. So, we keep the bicuspid aortic valve and we repair it if the valve is leaky. The aneurysm is completely resected and the bicuspid aortic valve is pulled up into the Dacron graft in order to resuspend it so that it can function normally again. This accomplishes the two goals of restoring a normal bicuspid aortic valve while replacing the aortic aneurysm. This is a specialized procedure, the David procedure, and look for tertiary care centers or centers of expertise who will be able to offer this procedure for your particular problem.

The Ross Procedure

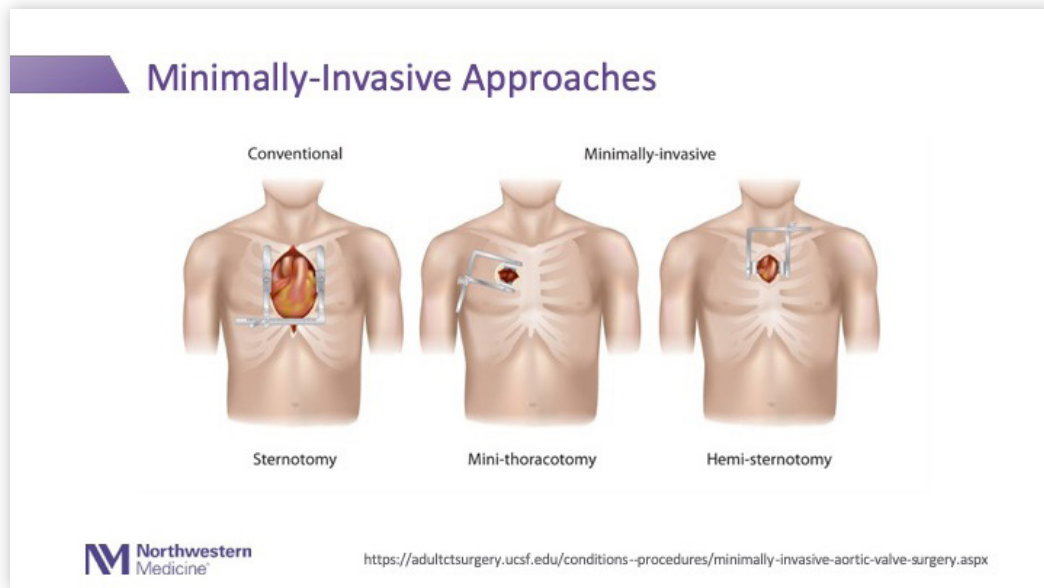


Dr. Chris Malaisrie: The Ross procedure involves replacing the aortic valve with a patient’s pulmonary valve. The first step is to remove the diseased aortic valve and then take the patient’s pulmonary valve, which is right next to the aortic valve on the heart, and then put that pulmonary valve in the aortic position.

You may ask, “What happens to that area in the pulmonary valve that’s no longer there?”

That valve is then replaced with what we call a homograft, a cadaveric pulmonary valve. This, if you pay very close attention, is a complex procedure that takes longer to do than a simple aortic valve replacement. It is a double valve procedure. But, these procedures are very good procedures for young patients with non-repairable bicuspid aortic valves where artificial valves are not the ideal situation for those patients. There’s a special case for these Ross Procedures, too.

Minimally-Invasive Approaches



Dr. Chris Malaisrie: A few words on minimally-invasive and transcatheter procedures.

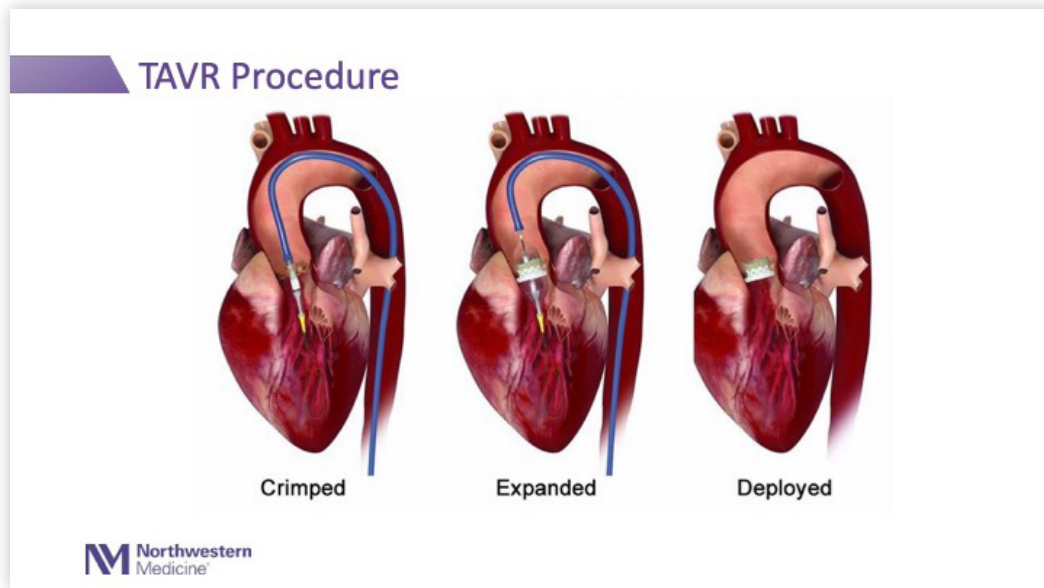
The approach for surgery is very important.

I recently had a patient who was 55 years old. I think one of the patients on HeartValveSurgery.com, as a matter of fact, who's an executive and really needed to get back to work as soon as possible. The approach for open-heart surgery is what most people think of on the left is an up-and-down incision, dividing the breastbone, exposing the entire heart.

In fact, many times, if it's just a simple aortic valve replacement, the approach can be done minimally-invasive with a keyhole incision either through a upper hemi-sternotomy, seen on the right, or my favorite approach, which is in the middle, in mini-thoracotomy, which is a keyhole incision between the ribs.

We can still do open-heart surgery, remove the aortic valve, and replace it either with a tissue or mechanical valve, and that particular patient I was talking about earlier had a very short length of stay in the hospital - three days, and was able to return to work in about two weeks. The minimally invasive procedure I think affords a very quick recovery.

Transcatheter Aortic Valve Replacement (TAVR)

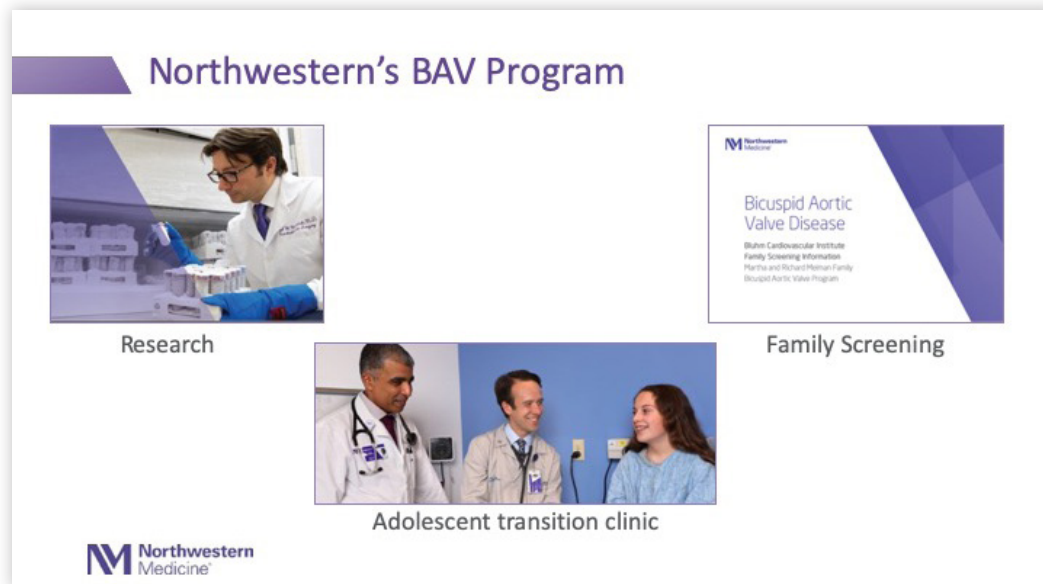

Dr. Chris Malaisrie: There are some patients that are high-risk for any sort of open-heart surgery. We're talking about 70-year old or 80-year-old patients with medical problems that can inhibit a normal recovery after standard cardiac surgery.

In these patients transcatheter aortic valve replacement, or TAVR, is an option for bicuspid aortic valves with aortic stenosis.

Here is a diagram illustrating that procedure. The valve is delivered through the artery in the leg through a small puncture site, no incision. Cardiopulmonary bypass, or the heart-lung machine, is not required for this procedure. The valve is crimped on a thin catheter, and once we deliver the valve into place inside the heart, then we briefly pace the heart in order to keep it from pumping blood, and then we can inflate a balloon or deploy the valve into position where it functions as it should on the right there fully deployed. This is an option I think for high-risk patients.

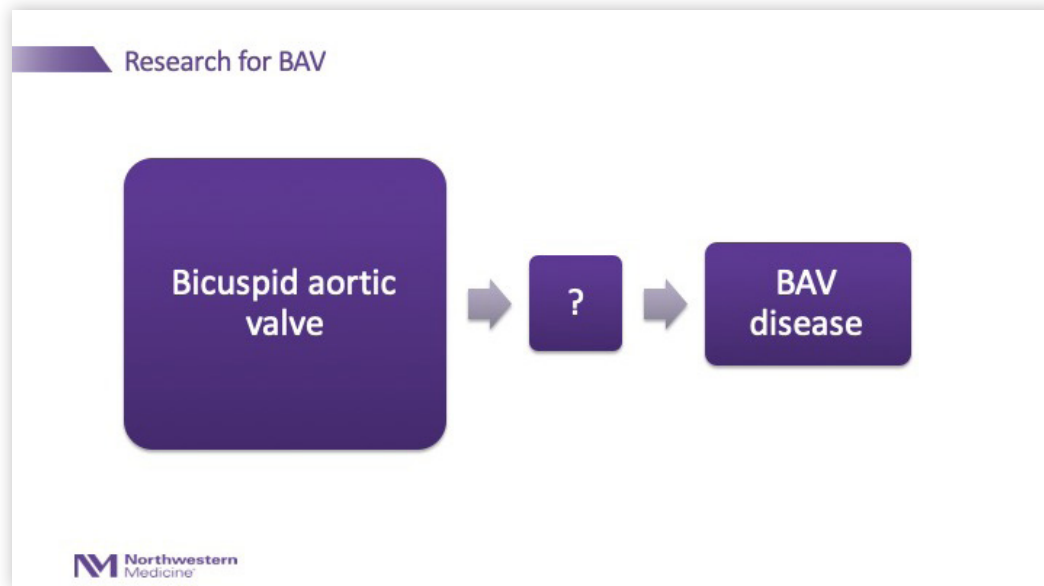
Northwestern's Bicuspid Aortic Valve Program



Dr. Jyothy Puthumana: I'll briefly talk about the research that is happening here. Dr. Fedak does most of our basic science work with resected tissue and combines it with some of our MRI imaging. Some of you may have seen publications from Northwestern that include the characterization of tissue in bicuspid aortic valve and some of the forefront in research.

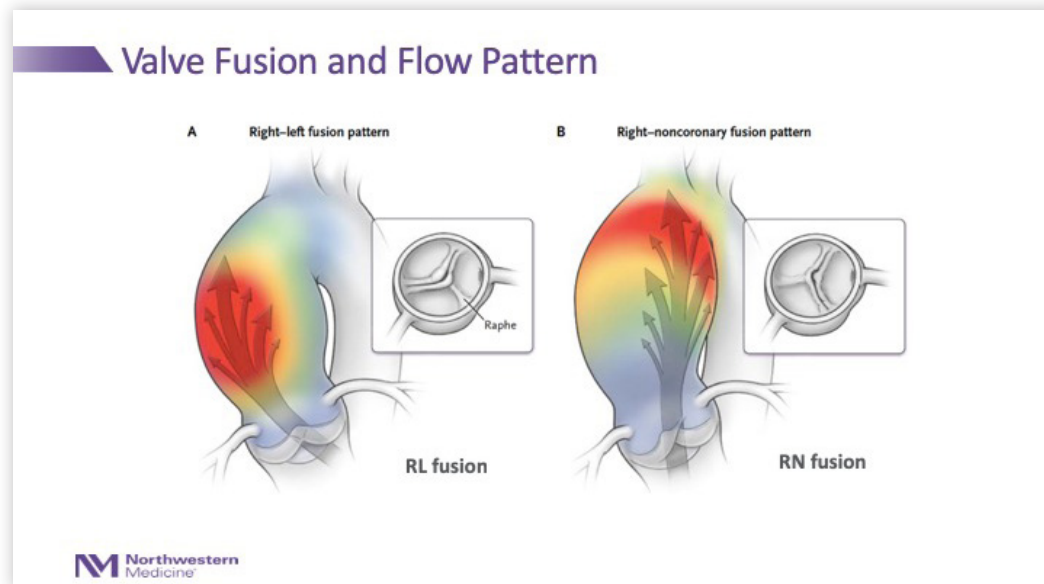
Chris talked about Northwestern's Bridge Program, mainly with the goal of transitioning children between the ages of 16 to 26 who have been in the care of a pediatric cardiologist as they transition to adult care. Most of the patients that we are seeing at this clinic are patients who have mostly had procedures done as infants or as children, whether it's a narrowed valve or an aneurysm repair, and may need repeat evaluation and potential surgery procedure in the future. The main goal of this Bridge Program is to transition patients and to follow them very closely.

Researching Bicuspid Aortic Valves



Dr. Jyothy Puthumana: We have a comprehensive bicuspid valve program that in addition to the medical, the surgical, the pediatric component, and Dr. Fedak’s basic science component, we have the radiology and cardiac MRI component to it. Erin Crawford is our nurse coordinator who helps coordinate our research and clinical program. The main goal of the research has been to have patients with bicuspid aortic valve disease and to look at what are the manifestations of disease and are we able to better identify or better triage patients into different categories as to those who are likely to progress versus those who are not, looking for new markers of disease that can progress faster or slower.

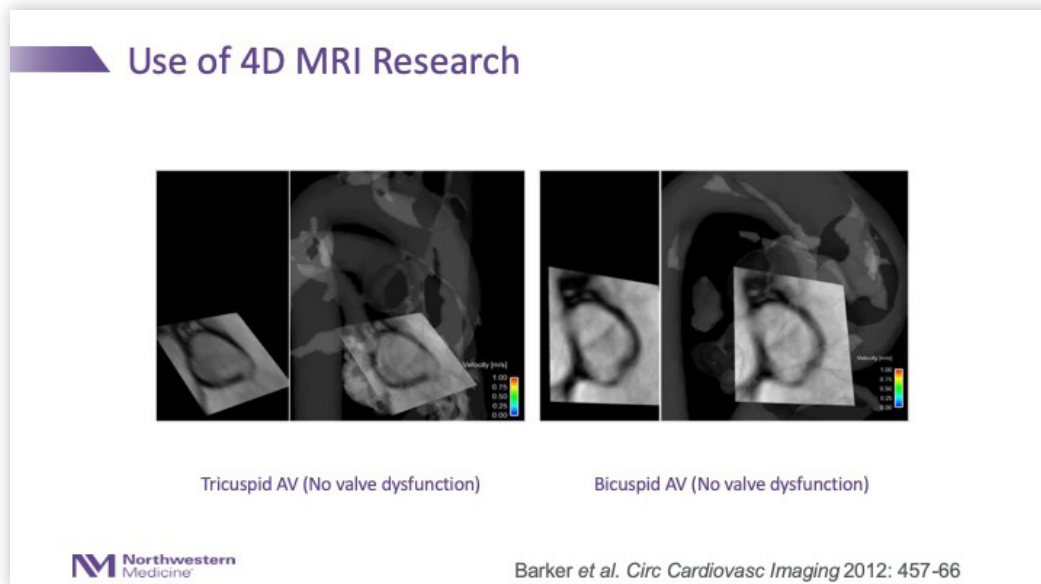
Valve Fusion & Flow Patterns



Dr. Jyothy Puthumana: Here we are looking at the imaging piece of things and how it correlates with actual tissue abnormalities seen in bicuspid valve. What we see in these two images on the left is common fusion patterns that are seen in a bicuspid valve. What we see in these two images is depending on how the bicuspid orifice is oriented, the flow across the valve has a predominant effect on different parts of the aorta.

A lot of the work that has been done by colleagues in radiology and cardiac MRI who have tried to identify the different morphology and to see if it was able to better characterize patients about the location of the most abnormalities. What you see here in red is the location of the highest stress on the aorta, and the thinking is that maybe the region that is likely to progress over the course of time.

4D-MRI Research



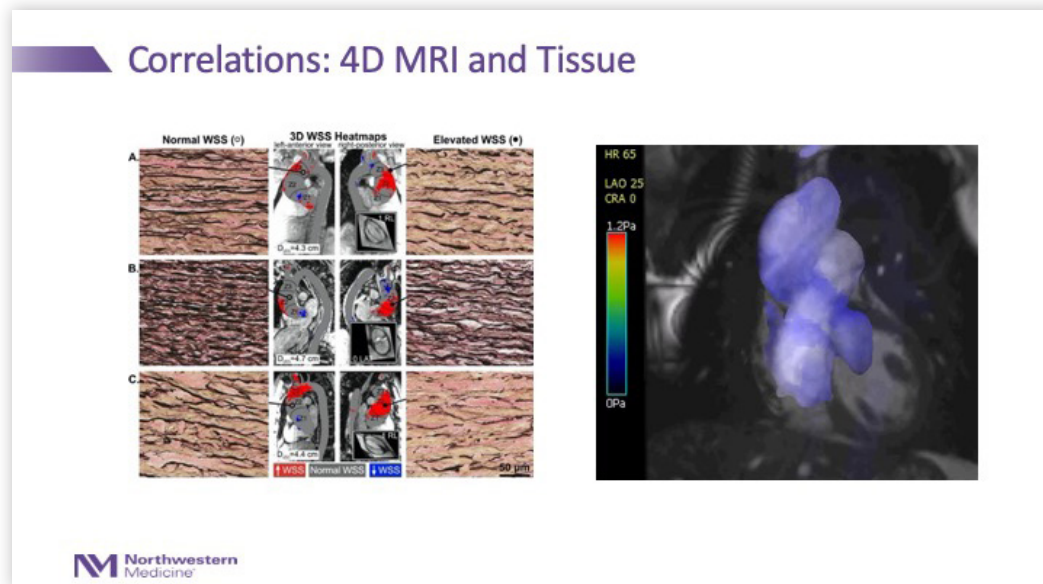
Dr. Jyothy Puthumana: These videos that you're seeing are images from the 4D flow imaging. What our colleagues, Dr. Michael Markl and Alex Barker, did on this particular paper, what they're being able to do is to tag flow across the aortic valve to the aorta. What you see on the left image is a normal, tri-leaflet aortic valve. You can see that when you tag the flow along, the flow tends to be nice and laminar.

The highest velocity of flow is right at the center and then the velocity decreases as you go along to the peripheries indicated by the greens and the yellows.

The right image shows a patient with a bicuspid aortic valve, and you can see on the image that the valve is opening well. This is not a valve that is either narrowed or is a valve that's leaking, but in spite of that, what you appreciate with this new technology is how the flow across the valve tends to be very eccentric and the flow has different effects on the different locations of the aorta.

There is a lot of work that has been done at Northwestern showing the benefit of this additional 4D flow imaging in being able to stratify bicuspid patients with and without aneurysms into different subgroups and their family members.

4D-MRI & Tissue Correlations



Dr. Jyothy Puthumana: This slide takes our research to the next step. I talked about Dr. Fedak and the collaboration that we have. If you look on the left-side image, what he – among our patients who are part of the study who have had to have the aneurysm resected by Dr. Malaisrie, what we have seen – and these are all patients who have undergone MRIs and MRIs with 4D flow imaging prior to their resection.

What we've been able to show is that what we see on the MRI as areas of high impact, high stress are the areas of the aorta that are more disintegrated, disorganized. So, what you see on the left screen are patients where the wall, the WSS's (wall shares stress) at parts of the aorta that do not have much stress as indicated by MRI where the tissue architecture seems to be intact.


In contrast, the part of the aorta that has more wall share stress as identified by MRI non-invasively are the parts of the aorta that when looked at under the electron microscope shows more tissue disintegration. Dr. Fedak has then gone on to show presence of some of the tissue biomarkers that indicate higher likelihood of elastin and other tissue breakdown. We've taken it from a non-invasive imaging standpoint on to the lab to show that what we are seeing has a role in being able to identify patients who have more tissue disintegration.

Dr. Chris Malaisrie: Let's go onto the questions and answers. I know we probably have some pretty good questions. The patients are very well-educated, and I get some excellent questions in clinic.

Questions & Answers

Bicuspid Aortic Valve Progression

Selene asks, “If you are born with a bicuspid aortic valve... Is aortic stenosis and surgery inevitable?”

 Northwestern
Medicine®

Adam Pick: We have received a flood of questions from the patients. The first one is coming in from Selene, and she asks a great question. “If you are born with a bicuspid aortic valve, is aortic stenosis and surgery inevitable?”

Dr. Jyothy Puthumana: Thanks, Selene, for asking this question on behalf of all the patients. Very important question and very important since 2% of us have a bicuspid valve. So, it’s very important to know how many are going to end up needing a surgery. What we know from studies that have now been following patients longer than 30, 35 years is that close to half the patients, anywhere from 45 to 50% of patients, will end up needing surgery in their lifetime if they are born with a bicuspid valve.

What is the usual timing of surgery? Most of the patients end up needing a surgery somewhere in the 50 to 60 age group. There are obviously children who

we see that have had surgery very young, and we've also seen patients much older than that.

Your question specifically addresses this, is aortic stenosis, and that's an important point to make because that is the most common manifestation of bicuspid aortic valve disease. We know that aortic stenosis is degeneration of the aortic valve that causes calcium to build up and restricts the valve opening that can happen to all of us as we get older even with the normal three-leaflet valve, but those with a bicuspid valve, it tends to happen maybe 15 years or even 20 years earlier than it would happen in a patient who does not have a bicuspid valve.

BAV Tissue Valve Re-Operations

Steve asks “I received a tissue valve and an arch replacement 4 years ago. As a 60-year old male is this advantageous if/when the valve needs to be replaced?”



Adam Pick: Steve asks, “I received a tissue valve and an arch replacement four years ago. As a 60-year-old male, is this advantageous if/when the valve needs to be replaced?”

Dr. Chris Malaisrie: Steve asked a great question here because he has a tissue valve and durability is a concern for younger patients. But, I think you rightly chose a tissue valve at his age group. We estimate that a 60-year-old patient who takes a tissue valve, they have a durability of about 15 to 20 years with that tissue valve, so that’s pretty good.

Where does that leave Steve when he’s 75 or 80 years old should the valve need to be replaced? I think he’s very well-positioned for a “Valve-in-valve” procedure. The Valve-in-valve procedure is a transcatheter procedure. So, the next operation for Steve does not have to be repeat open-heart surgery. This is a TAVR procedure where we deliver the valve through the groin, and the tissue valve stent becomes a very good landing zone for the TAVR valve. Steve is very well-positioned should he need a valve replaced for transcatheter procedure in the future.

Valve-Sparing Procedure Timing

Ron asks, “What size aneurysm would the doctors operate IF my bicuspid aortic valve is functioning normally?”



Adam Pick: Ron asks, “What size aneurysm would the doctors operate if my bicuspid aortic valve is functioning normally?”

Dr. Chris Malaisrie: Ron is concerned about his aortic aneurysm and rightly so because aneurysms as they grow have a greater risk of rupture or dissection, which are aortic emergencies. We know that 50% of patients with bicuspid aortic valves have an associated aortic aneurysm. So that’s part of our research is to determine what size is the appropriate size, but guideline recommendations say that we should never let the aortic aneurysm get above 5.5 centimeters.

That is one number that Ron should remember. In many centers, including ours, that are centers of excellence who can offer an aortic root replacement with low operative risk meaning that the patients don’t have to worry about complications from this procedure. Then 5.0 centimeters is another threshold number where we think about offering a preventive aortic surgery in order to prevent an aortic catastrophe.

Risk Factors for BAV

Melinda asks, “What can I do to avoid surgery for my bicuspid aortic valve? Should I control my weight and blood pressure?”



Adam Pick: The next question comes in from Melinda about risk factors for BAV, and she says, “What can I do to avoid surgery for my bicuspid aortic valve? Should I control my weight and blood pressure?”

Dr. Jyothy Puthumana: Thanks, Melinda, for asking this. In my clinic, this is the most important question that patients ask as to how best can they take care of the valve to either delay or postpone or hopefully never need surgery.

What we know is that the risk factors that predispose patients for the valve to get calcified and narrowed causing aortic stenosis are mostly the same risk factors that also are present in patients who develop blockages in the arteries of the heart and atherosclerosis. What we know is patients who have higher cholesterol, who have higher blood pressure, who smoke, who are overweight – these are all the risk factors that could increase the speed at which the valve can calcify.

Having said that, you really don't have too much control in spite of having all optimal risk factors. If your cholesterol levels are ideal, if your blood pressure's ideal, your valve can still degenerate just because it is a bicuspid valve. Just as we saw in the cartoon that they made with the echoes, the flow across the valve is what damages the margins of the valve, and when the valve margin damages, there is calcium that deposits there that causes the valve to degenerate.

The newer research into this looks at specific cholesterol markers. Some of you may have had blood tests done looking at lipoprotein. The thinking is that if patients have elevated lipoprotein, this may be patients whose valve may calcify a little faster and may be a role to lower the cholesterol, even if the cholesterol values are close to normal, but studies that have looked at lowering cholesterol with cholesterol medication in large groups of patients have not shown a decrease in progression. I think it's a long-winded answer to your question, but healthy lifestyle definitely can delay your progression but not prevent it altogether.

Dental Infections

Jeanne asks, “Since my BAV replacement, I have developed infections in two teeth implants. Is this significant? What should I do to prevent this?”



Adam Pick: Jeanne asks, “Since my BAV replacement, I have developed infections in two teeth implants. Is this significant? What should I do to prevent this?”

Dr. Jyothy Puthumana: There are times for this question, and usually patients have questions in two ways. One is since I have a bicuspid valve, do I need to do anything different when I go to the dentist, but in your case, it looks like it may be coincidental that you are having more problems with the implants and with the teeth following your surgery.

The replacement of your bicuspid valve, irrespective of the type of valve, and the concomitant medication that you’re taking should not by itself caused you to have more gum disease or infection in the mouth. Having said that, it is extremely important that any oral infection is well-treated and addressed and, in fact, right when we see our patient from the first time on, we reemphasize the need for extremely good dental hygiene both on a regular basis and with visits to the dentist every – at least twice a year.

We know that most of the time when patients end up having an infection on the valve, the common organism is usually an organism that's present in the mouth. We have good data to show that poor dental hygiene predisposes patients to the risk of getting an infection on the valve. Dental hygiene is key and very important part of taking care of your bicuspid valve.

 SAVR v. TAVR

Joe asks, “I’m a 62-year old BAV patient. Are there any activity restrictions for a person with a TAVR-placed valve vs a SAVR?”



Adam Pick: Joe asks, “I’m a 62-year-old bicuspid aortic valve patient. Are there any activity restrictions for a person with a TAVR-placed valve versus a SAVR?”

Dr. Chris Malaisrie: This is a question for patients who are recovering from either procedure. The great thing about the TAVR procedure is that the recovery is so quick. Joe is only 62 years old, but I’ve seen 80-year-old patients get the TAVR procedure and be home within one to two days with exercise restrictions of only one to two weeks and back to the golf course or tennis court where they really want to be. That’s a lot faster than for surgical aortic valve replacement, but I think for a 62-year-old patient with bicuspid aortic valve, I would take a really close look at a minimally invasive open-heart procedure. We can do open-heart procedure where we remove the bicuspid aortic valve and replace it with either a mechanical or tissue valve through a keyhole incision. In those types of cases, you can be home within three to five days from the hospital and back to normal activity in about two weeks. For Joe, I think both procedures are available to Joe, but probably minimally invasive aortic valve replacement would be the preferred choice for him because he’s bicuspid.

The slide features a purple header bar with the text "BAV Symptoms". The main content is centered text in a bold, dark font. At the bottom left of the slide is the Northwestern Medicine logo.

BAV Symptoms

Judy asks, “I have BAV. Should I be concerned when I get heart palpitations, twinges or short period of pain in my chest?”



Adam Pick: Judy asks, “I have bicuspid aortic valve. Should I be concerned when I get heart palpitations, twinges or short periods of pain in my chest?”

Dr. Jyothy Puthumana: Judy, thanks for asking this question. It is very important – as we had mentioned in the beginning, there are three manifestations in bicuspid aortic valve disease, either narrowing of the valve, stenosis; leaking of the valve, regurgitation; or aortic aneurysm.

The first two conditions, whether it’s a narrowing of the valve or a leaking of the valve, eventually it will cause symptoms, and mostly patients complain of feeling short of breath initially with exercise but shortness of breath that can progress indicating that the valve is getting into more trouble.

Patients can have palpitations if there is extra workload on the heart. The aneurysm is one condition where patients can continue to have enlargement of the aneurysm without significant manifestation of symptoms.

I think for your specific situation, what is important that you are educated on is what is happening to my bicuspid valve. Is it mild, moderate, or severely stenotic? Is it mild, moderate, or severely regurgitant? What is the size of my aneurysm? Once you have all that information, you should be able to tease out whether the symptoms could be coming from your bicuspid valve, or if it's independent and if it's from some other issue from a heart standpoint but may not be from the bicuspid valve.

Homograft Replacements for BAV

William asks, “Is it common that a homograft is used for bicuspid aortic valve replacements? Why or why not?”



Adam Pick: William asks, “Is it common that a homograft is used for bicuspid aortic valve replacements? Why or why not?”

Dr. Chris Malaisrie: It sounds like William has done the homework on valve choice. Homograft now is not being as commonly used as before in elective cases. The reason is because tissue valves constructed from animal parts, so the pig and cow valve, have just become so durable with newer and newer technology that homografts, which are human aortic valves, are used less and less. There is one particular case where we do use homografts, and those are cases where the bicuspid aortic valve patient develops an infection in the heart valve, which we call endocarditis. Sometimes those infections can be fairly destructive in the heart, in which case we would need to use a homograft in order to reconstruct the damage that has been done by the bacteria as well as replace the valve. Homograft is less used in elective cases but still commonly used for heart valve infections.

Mechanical Valve Replacements

Tom asks, “I’d like to have a ‘one-and-done’ procedure so I’m thinking about a mechanical valve when I need surgery. Will mechanical valves always need patients to be on blood thinners?”



Adam Pick: Tom asks, “I’d like to have a one-and-done procedure, so I’m thinking about a mechanical valve when I need surgery. Will mechanical valves always need patients to be on blood thinners?”

Dr. Chris Malaisrie: Tom asked a really exciting research question, and I’d like to tell the whole group that blood thinners for mechanical valves is constantly changing. Right now, mechanical valves have to be maintained on the blood thinner called Coumadin or Warfarin.

One recent advance is with the CryoLife On-X valves is that the Coumadin level can be lower than standard Coumadin levels, so that’s the new breakthrough that’s happened recently. Now, there are currently studies going on looking at alternatives to Coumadin, particularly the trial called PROACT Xa trial, which is listed on clinicaltrials.gov.

We will be participating in that trial as well, and that trial is designed to look at alternatives to Coumadin we call DOACs or NOACs, so direct oral anticoagulants, which we've found to be safer in conditions such as atrial fibrillation and blood clots but has not yet been tested in mechanical valves until now.

This [PROACT Xa](#) trial will be looking at newer anticoagulation for mechanical valves. I think that's going to be a really exciting option for patients in the future if the trial is positive.

Adam Pick: With that exciting response, we're going to conclude the webinar, but please don't exit the webinar just yet.

On behalf of the entire community at HeartValveSurgery.com and all the patients with valve disease, I'd like to extend an extraordinary thank you to Dr. Malaisrie and Dr. Puthumana for sharing their expertise with us today.

As we end the webinar, I'd like to thank you for your participation in this community event and your support of HeartValveSurgery.com.

Educational Resources

Since 2006, HeartValveSurgery.com has developed several resources to help you better understand your diagnosis, your treatment options and your recovery.

Listed below, please find resources created exclusively for patients and caregivers. We hope they educate and empower you.

- [Adam's Free Patient eBooks](#) - Download 7 free eBooks about heart valve disease and treatment options for aortic, mitral, pulmonary and tricuspid valves.
- [Heart Valve Learning Center](#) - Visit the Heart Valve Learning Center to access over 1,000 pages of educational information about valvular disorders.
- [Patient Community](#) - Meet people just like you in our patient community. There's nothing better than connecting and learning from patients who are sharing their stories in our community.
- [Surgeon Finder](#) - Find and research patient-recommended heart surgeons that specialize in heart valve repair and heart valve replacement procedures.
- [Heart Hospitals](#) - Learn about medical centers that have dedicated teams and resources that specialize in heart valve therapy.
- [Adam's Heart Valve Blog](#) - Get the latest medical news and patient updates from our award-winning blog.
- [Educational Videos](#) - Watch over 100 educational videos filmed by the Heart-ValveSurgery.com film crew about heart valve surgery.